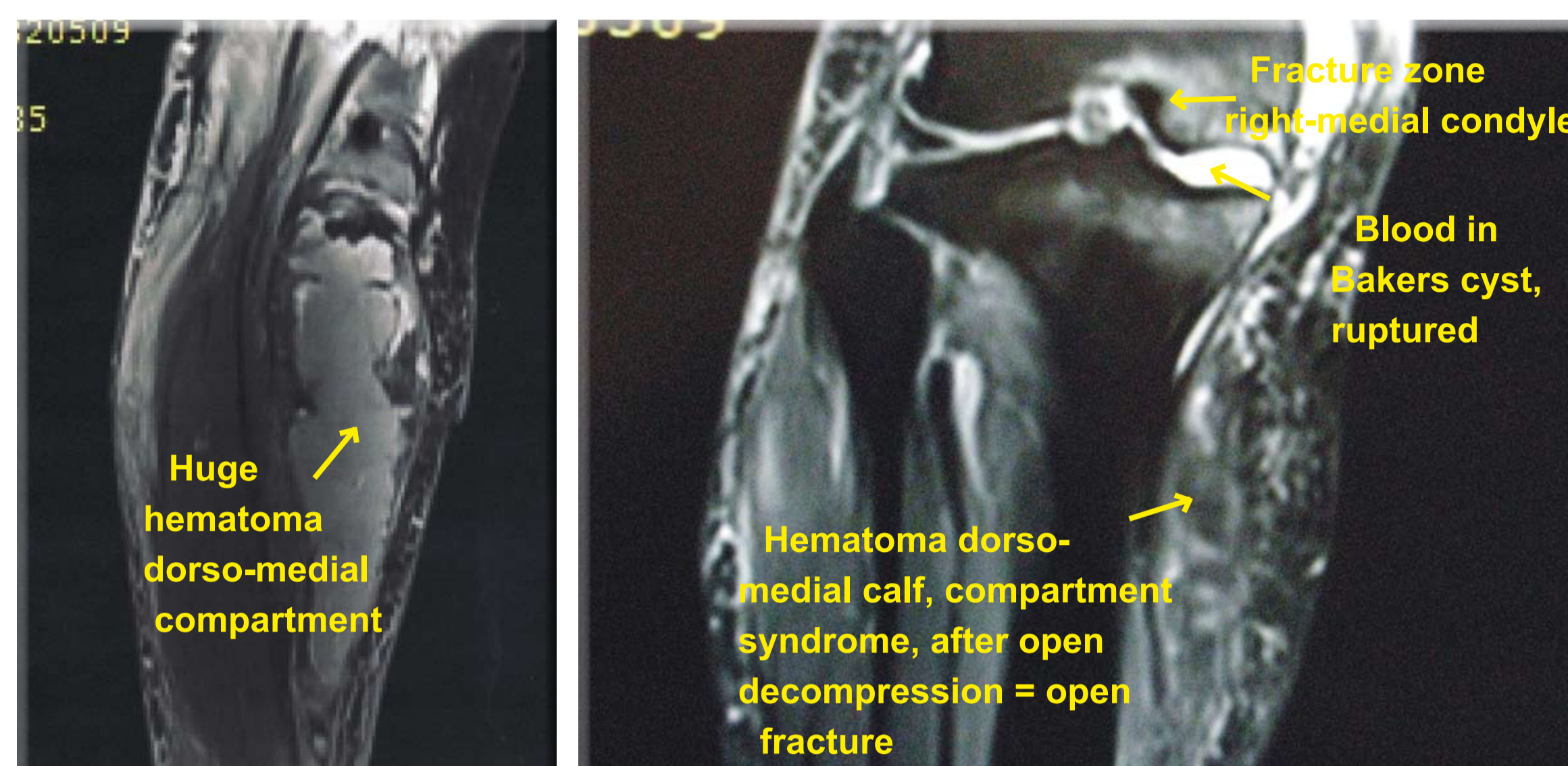


Reduction of Edema and Pain on Surgical Wounds with Polymeric Membrane Dressings*

Peter Schmid, MD, PhD, FACS, General and Vascular Surgery,
Ziegelrain 18, 5000 Aarau, Switzerland

INTRODUCTION


A 77 year old white female with an arthrotic right knee was seen for a painful lower leg swelling. She was placed on low molecular heparine and oral anticoagulation with the coumarine derivative Marcoumar® for suspected deep venous thrombosis. Despite INR ratios within therapeutical limits and Trendelenburg position the swelling and the pain increased and the patient had to be admitted to the hospital. Color duplex scanning revealed a huge hematoma and open veins; these findings were confirmed by MRI.



On MRI a compression fracture of her medial femoral condyle was seen. Under Marcoumar® a massive bleeding into the joint and the baker cyst occurred. The cyst ruptured and the dorso-medial compartment of the lower leg was filled with blood. The patient suffered severe pain due to compartment syndrome. Decompression and evacuation converted a closed fracture into an open one with the risk of osteomyelitis. Due to concurrently administered low molecular heparin, the primarily closed and drained wound led to a massive hemorrhage. The wound had to be stuffed with towels at the bedside in the hemodynamically unstable patient. 24 hours later, the low molecular heparin was metabolized and the incision was secondarily closed under normalized coagulation parameters.

Aim

To demonstrate how we use polymeric membrane dressings to prevent pain and edema whilst facilitating healing when used on post-operative wounds.



Polymeric membrane dressings covering the lower leg.

METHOD

Polymeric membrane dressing applied to the surgical site immediately after evacuation of hematoma.

The initial plan was to wait for 2 months before performing the total knee replacement since we had a closed fracture converted to an open fracture with the inherent risk of an infection at the fracture site and because the soft tissue was severely damaged due to the compartment syndrome. This approach would have meant that the patient had to stay in bed for 2 months due to the fracture. However, the wound improved and 2 weeks later we did the total knee replacement based on the favorable local wound conditions.

Nine days after her knee replacement the wound healing was favorable.

We then believed that the Polymeric membrane dressings were unnecessary and switched to a standard post-op dressing. Within hours after replacing Polymeric membrane dressings with the conventional dressing the patient needed more pain medication and after 24 hours we removed that dressing and reapplied Polymeric membrane dressings. Once polymeric membrane dressings were reapplied the need for pain medication gradually decreased and the patient was discharged from the hospital 12 days after the total knee replacement with Polymeric membrane dressings on her leg.

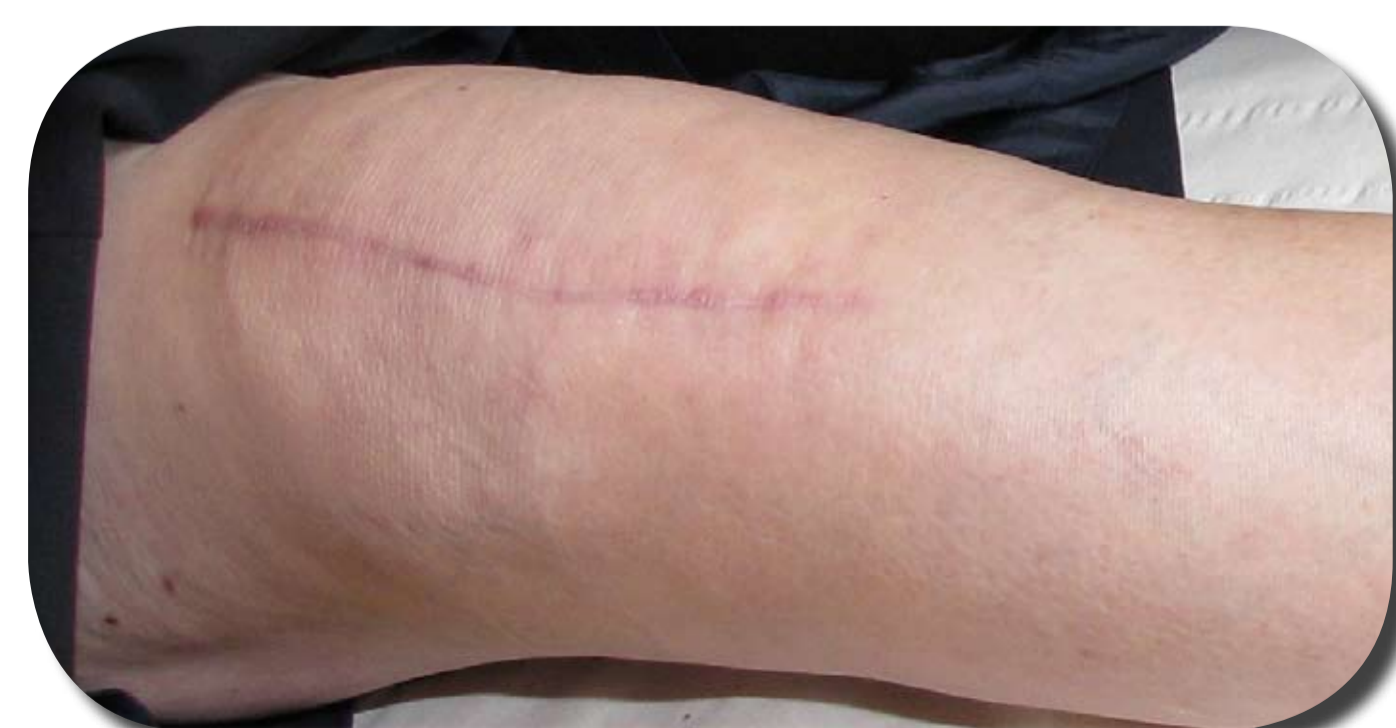Polymeric membrane dressings were finally discontinued 3 weeks after total knee replacement; the patient was fully mobilized by that time and after the dressing removal we observed no swelling after the withdrawal of the Polymeric membrane dressings.

RESULTS

Dramatic reduction in bruising, edema and pain during the time she was wrapped with polymeric membrane dressings after decompression of a compartment syndrome allowed for total knee replacement surgery after only 16 days instead of the anticipated 60 days. The patient recovered within less than a month from both compartment syndrome due to bleeding in a ruptured Baker's cyst and from total knee replacement. These excellent results are solely attributed to the wrapping of the leg with Polymeric membrane dressings.

DISCUSSION

During my 25 years as a vascular surgeon, with a private practice for the past 17 years specializing on patients with advanced peripheral vascular disease and challenging wound problems, I have always performed the dressing changes personally. Since initiating polymeric membrane dressings in my practice 3 years ago, I have experienced faster healing, less swelling, reduced pain levels and reduced infection rates in my patients. This experience suggests that further prospective trials should be done.

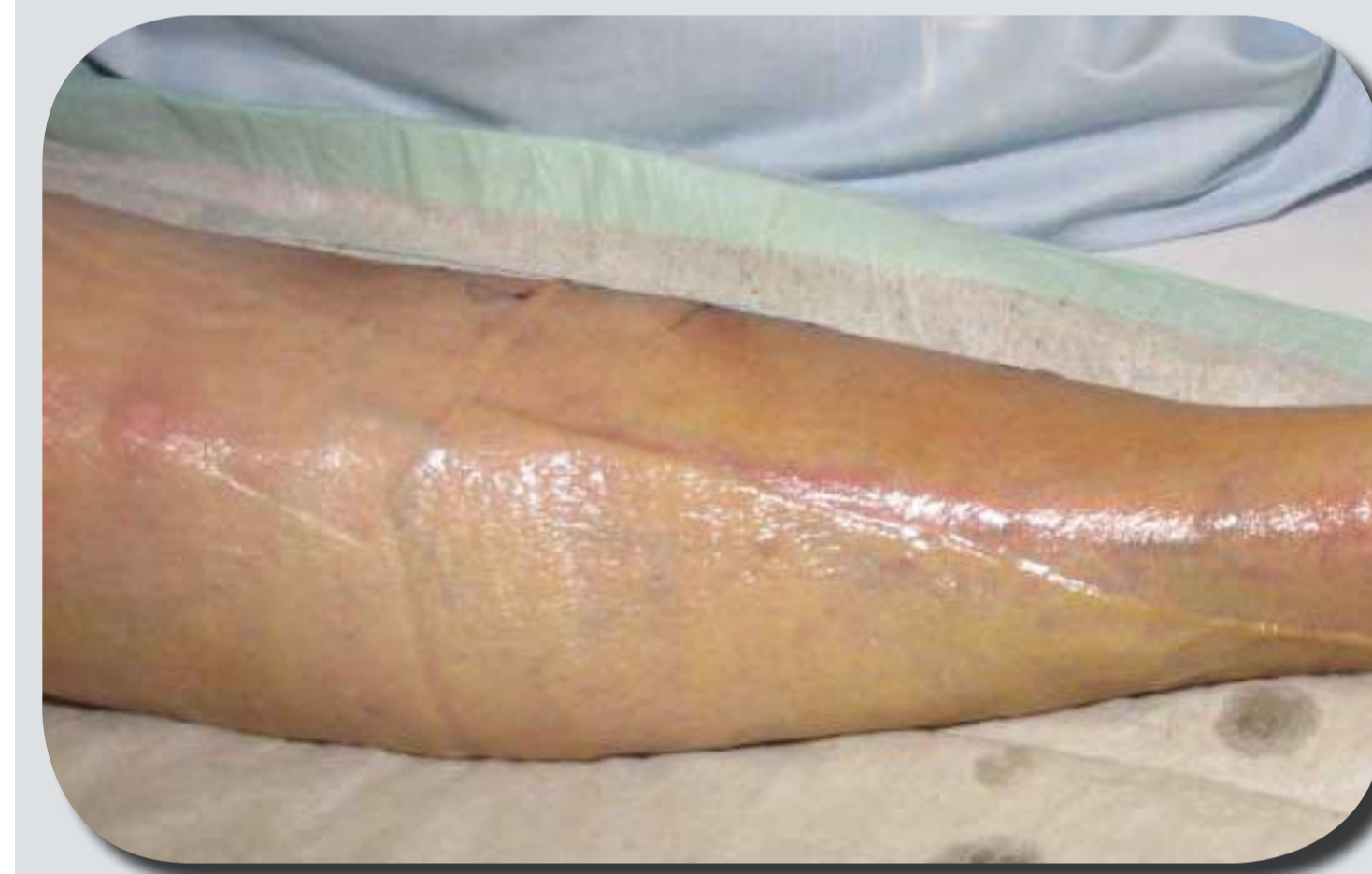
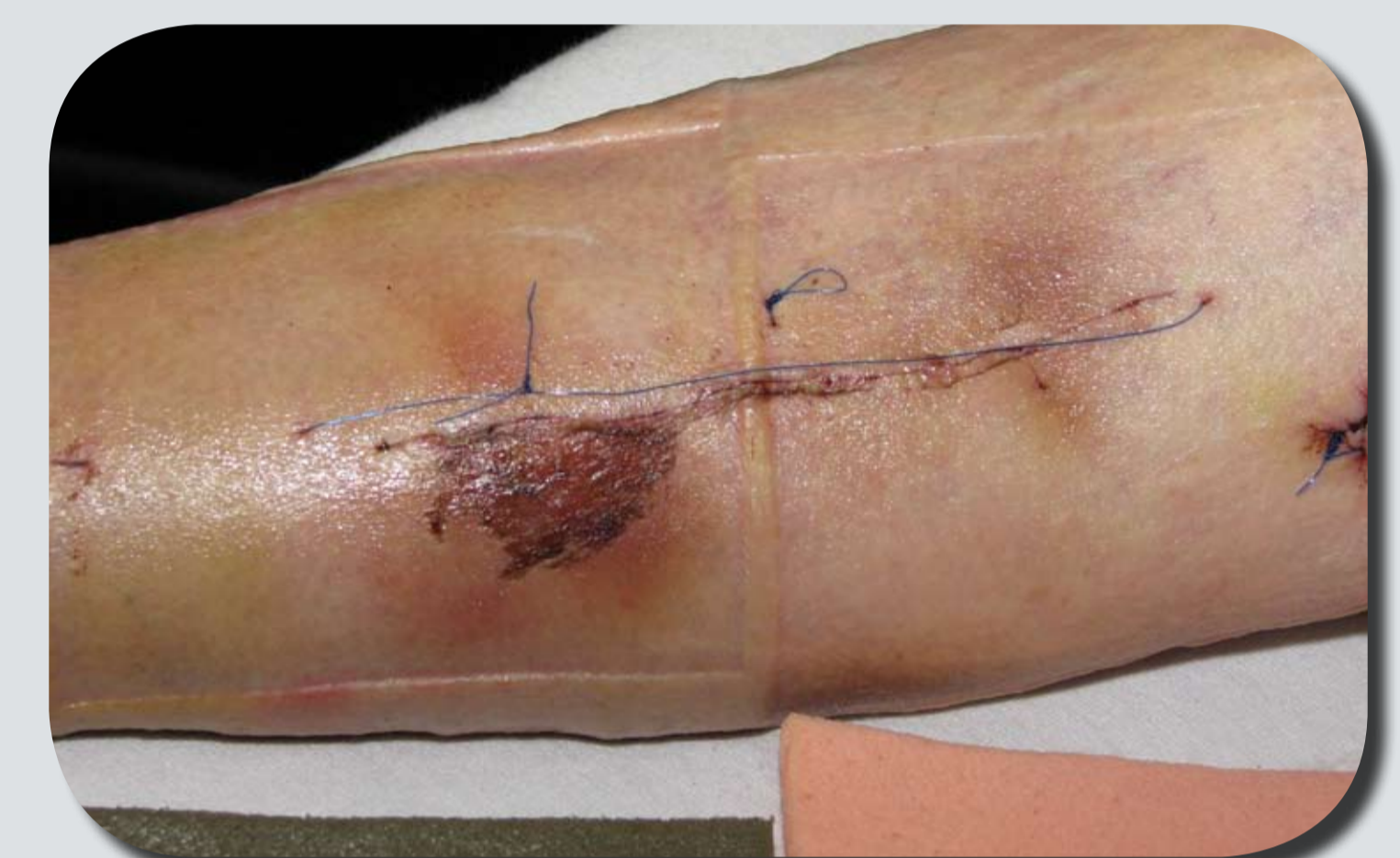
Follow up 3 months after the surgery. Full range of motion in the right knee, daily walking for hours without pain.

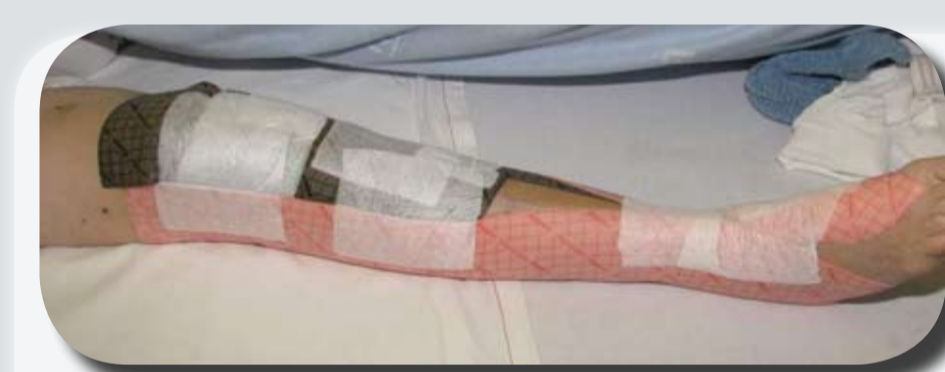
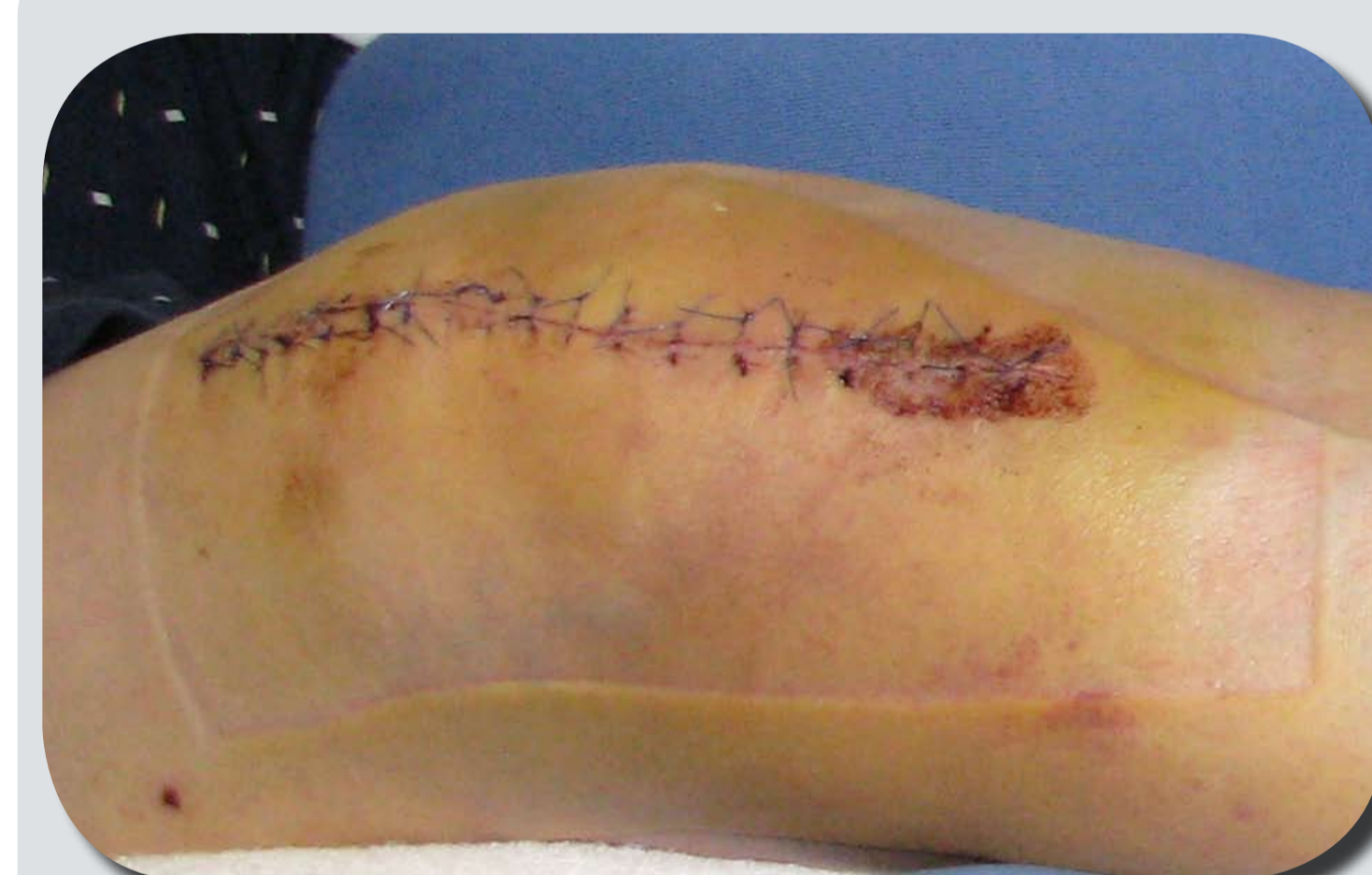Bibliography

1. Beitz AJ, Newman A, Kahn AR, Ruggles T, Eikmeier L. A polymeric membrane dressing with antinociceptive properties: analysis with a rodent model of stab wound secondary hyperalgesia. *J Pain*. 2004 Feb;5(1):38-47.
2. J.K Hayden, B.J. Cole. The effectiveness of a pain wrap compared to a standard dressing on the reduction of postoperative morbidity following routine knee arthroscopy; A prospective randomised single-blind study. *Orthopedics* 2003 Jan; 26 (1): 59-63.

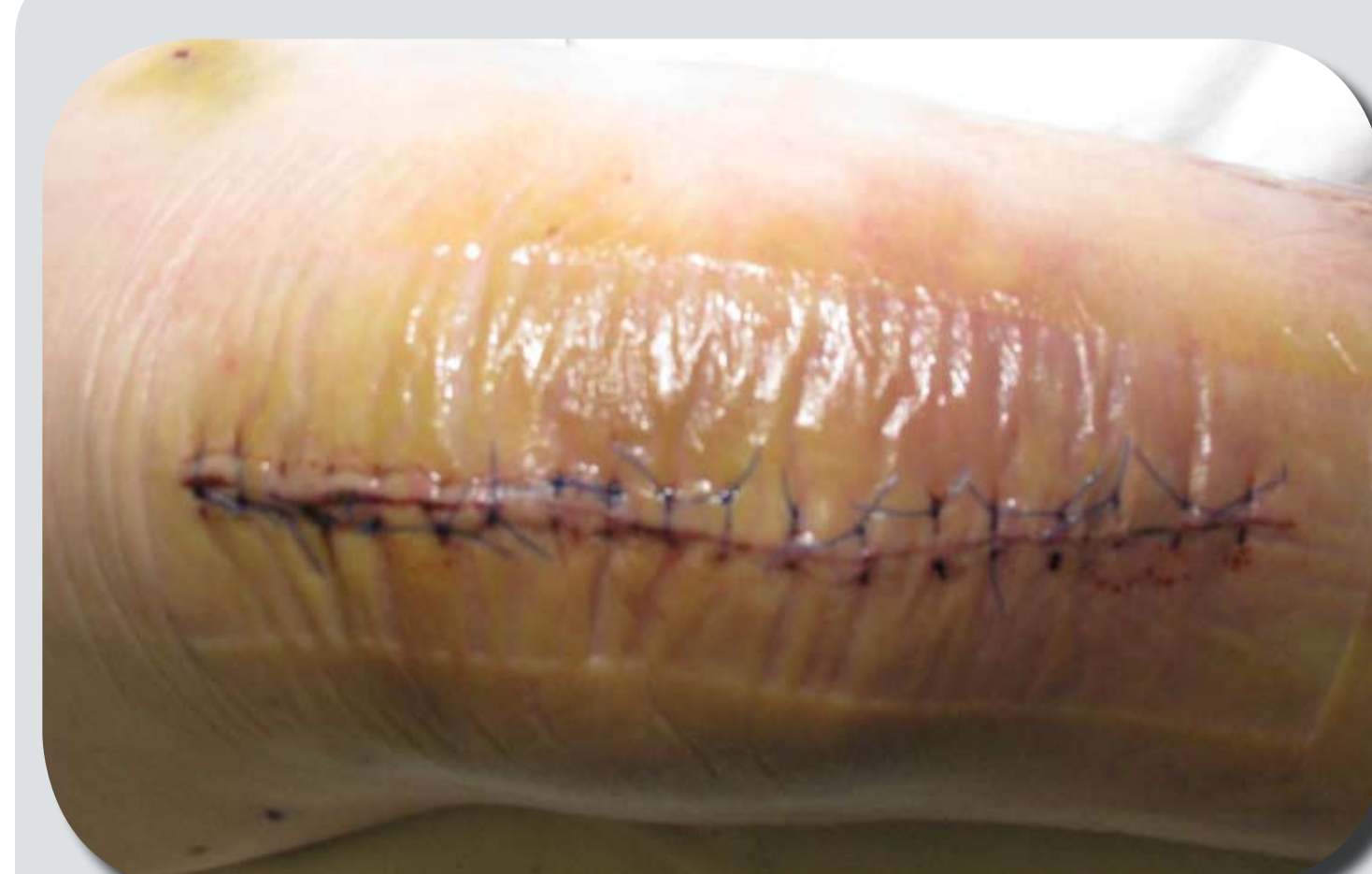2 weeks after open decompression of compartment syndrome and secondary closure 24 hours later. Polymeric membrane dressings have reduced the edema normally seen after this type of intervention. Polymeric silver dressing used over the breached skin. Photos to the right and below are 2 weeks after decompression of compartment syndrome.



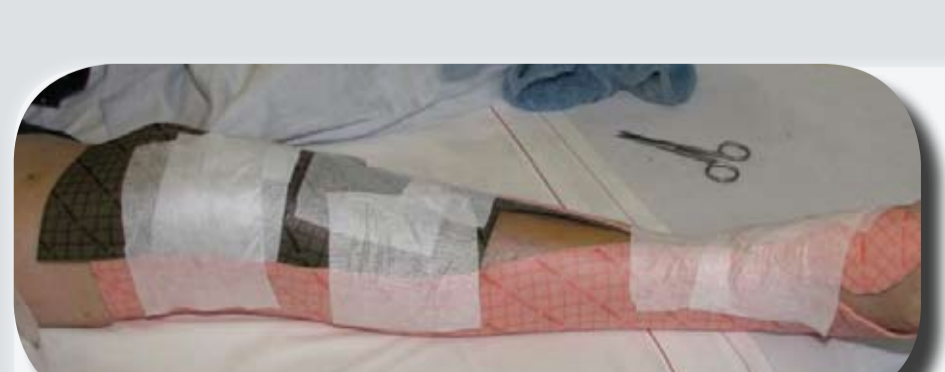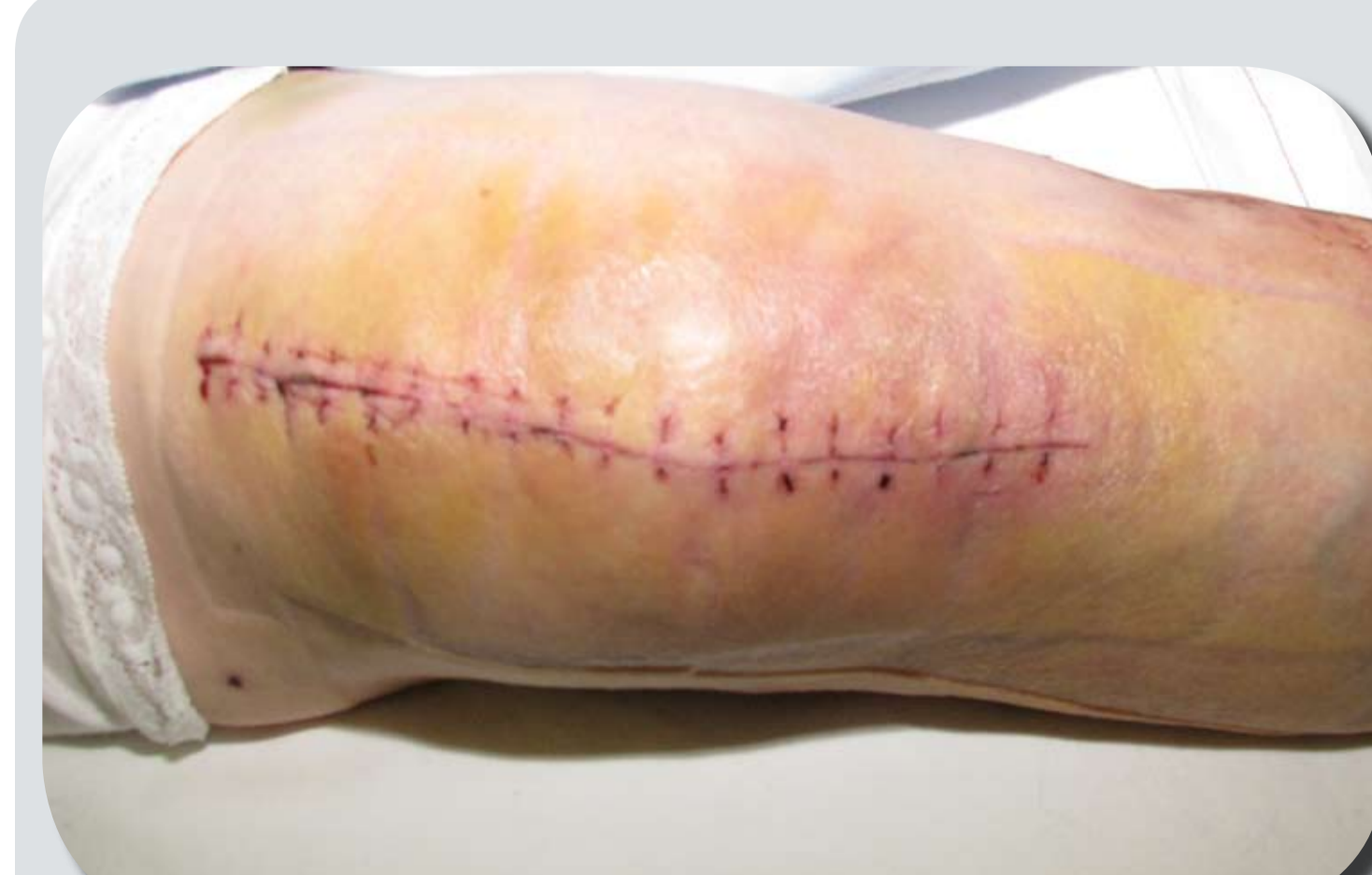Current surgical thinking is to postpone surgery for about 2 months to assure complete healing and persistent normalization of all infectious parameters prior to total knee replacement. Polymeric membrane dressings did reduce the edema and enhanced the wound healing to such an extent that it was considered to be medically safe to perform the surgery after only 2 weeks.



Nine days after the total knee replacement the wound was healing nicely and there was no visible swelling. A standard surgical dressing was applied instead of the polymeric membrane dressings. Within hours, the patient started complaining about pain and she needed again pain medication for the first time in a week.



The standard post-op dressing was removed 24 hours later since the patient continued to complain over pain and she asked for more pain medication. We noted that the swelling and bruising had increased substantially in the patients knee so we reapplied polymeric membrane dressings again.



Three weeks after the total knee replacement we discontinued the use of polymeric membrane dressings. This time the patient did not experience any problems with increased pain or swelling after the withdrawal of the polymeric membrane dressings.

*PolyMem® and PolyMem® Silver Wound dressing
Manufactured by Ferris Mfg Corp, Burr Ridge, IL 60527 USA. This case study was unsponsored. Ferris Mfg. Corp. contributed to this poster design and presentation.